



Received on 12 December, 2014; Received in revised form, 19 December, 2014; Accepted, 24 December, 2014

## UNUSUAL PRESENTATION OF NON-HODGKIN LYMPHOMA: VULVA GROWTH AND BREAST MASS IN THE SAME PATIENT

Yashpal Verma<sup>1</sup>, Ashok K. Chauhan<sup>1</sup>, Ramesh Sabharwal<sup>2</sup>, Jagjeet Singh<sup>3</sup>

<sup>1</sup> Department of Radiotherapy, PGIMS (UHS) Rohtak, India

<sup>2</sup> General Hospital, Department of Health, Kurukshetra, India

<sup>3</sup> Department of Medicine, PGIMS (UHS) Rohtak, India

### Keywords:

*Breast, Primary Non-Hodgkin Lymphoma,, Rare malignancy, Radiotherapy, Vulva.*

### Corresponding author:

Dr. Yashpal Verma,  
Medical Officer,  
Department of Radiotherapy,  
University of Health Sciences,  
Rohtak (INDIA).  
Contact no. +91-9416125026  
Email: [yashpverma@gmail.com](mailto:yashpverma@gmail.com)

### Abstract

Primary involvement of vulva or breast by non-hodgkin lymphoma (NHL) is known to occur uncommonly. Only 24 cases of NHL vulva and around 250 cases of NHL breast alone have been reported, so far; but none with simultaneous involvement of the two sites together. We report the **first** case having both sites involved in a 35 year old Indian female.

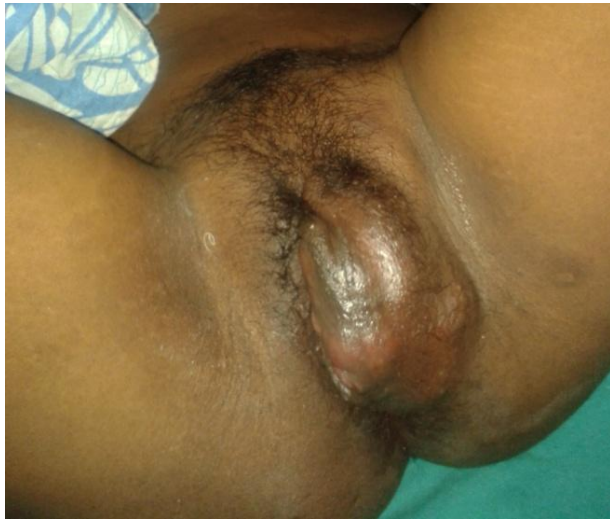## INTRODUCTION

Malignant lymphomas concern the female genital tract in 30% of cases. The majority (more than 90%) are non-hodgkin lymphoma (NHL), involving in order of frequency, ovary (49%), uterus (29%), fallopian tubes (11%), vagina (7%), vulva (4%).<sup>1</sup> So also is the breast involvement, accounting for less than 1% of all patients with Non-Hodgkin's lymphomas.<sup>2,3</sup> This case of NHL, in an Asian young female aged 35 years, presented as vulva growth along with breast mass, first ever reported simultaneous occurrence.

## CASE REPORT

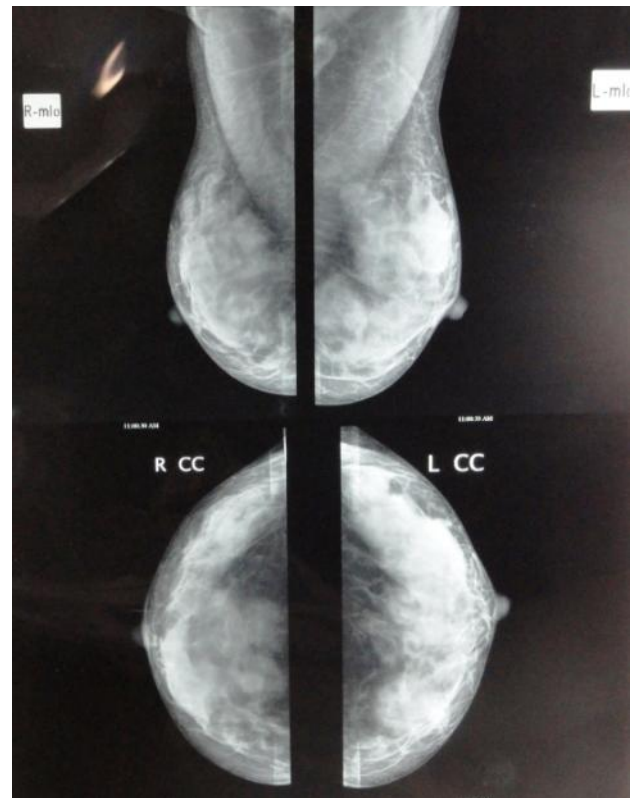
35 year old female of moderate built & nutrition, presented with mass involving external genitalia of three month duration and mass in both breast of one month duration, insidious onset, gradual increase in size, painless. There was associated complaint of difficulty in micturition and defecation. No history of unusual bleeding per vaginum or per rectum. No history of fever or significant weight loss or night sweats during the course of ailment. Past history of taking anti-tubercular treatment, 5 years back for being diagnosed as koch's chest. Non-tubectomised, menstruation regular, 3/30 days,

and last childbirth 11 years back. Examination revealed ulcero-proliferative vulva growth (left labia majora) of size 10 cm x 8 cm, firm to hard, extending more posteriorly (Fig 1)



**Figure 1**

Per vaginal examination showed no abnormality other than partial obliteration of introitus, as mass effect. Per rectal examination revealed extension of disease to anterior & left lateral wall of anal canal, with adherent mucosa. Both breasts were tense and overlying skin showed venous engorgement. Smooth firm solitary mass of size 5x4 cm in left breast and 6x4 cm in right breast were palpable, none fixed to chest wall or skin. No history of abnormal discharge or blood per nipple. No association of size variation and menstrual cycle was observed. No neck, axillary or inguinal nodes were palpable. No hepatosplenomegaly was apparent on per abdominal examination. USG showed diffuse hypo echoic lesion in each breast, resembling enlarged lymph node. Mammography showed round smooth margin mass in each breast with loss of normal concavity of breast architecture (Fig 2).

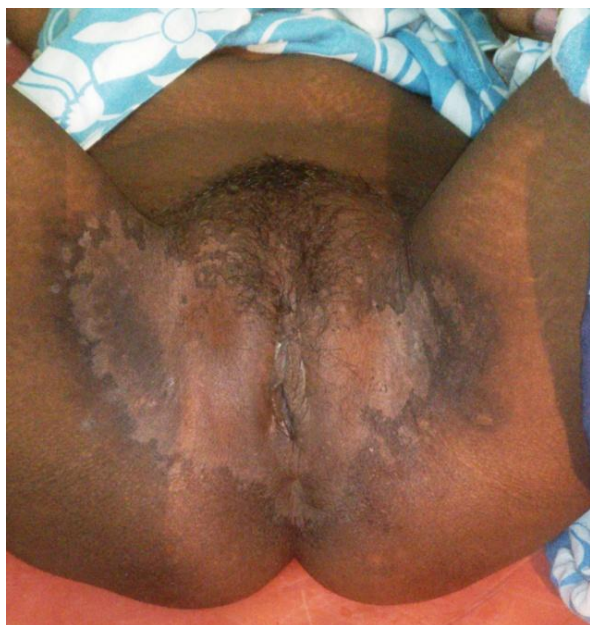

**Figure 2**

Chest X-ray was normal. USG abdomen showed multiple lymph nodes at porta, peripancreatic and splenic hilar region, largest 2.5 cm. Other organs were normal, no free fluid was seen. Vulvar biopsy & Immunohistochemistry showed LCA positive and CAM 5-2, CD 5, CD 20, CD 34, HMB 45, NSE, Synaptophysin, Chromogranin & MPO negative lesion concluded as undifferentiated diffuse NHL. FNAC of mass in both breasts also suggested NHL.

## TREATMENT

In view of fungating nature, external beam radiotherapy was given to vulva lesion, as 20 Gy/ 5 fractions in 5 days. Four weeks later patient was started on standard CHOP regimen chemotherapy. Three weeks after first course of chemotherapy, all lesions responded well and no significant lesion was apparent clinically (Fig 3) or radiologically.



**Figure 3**

No significant toxicity was observed and patient was doing well. Three more courses of chemotherapy were planned in view of good response. Unfortunately, patient developed jaundice after third course of chemotherapy and expired, cause of which could not be found despite extensive investigations.

**Table1.** Summary of NHL vulva reported so far.

Case no.	Year	Author	Histopathology	Age	Treatment
1	1937	Taussig	NHL Clitoris	63	NR
6	1990	Bagella MP	NHL	?	NR
7	1992	Nam JH	NHL	68	NR
16	1996	Kaplan EJ	NHL (HIV associated)	25 yr	CT, EBRT
17	1998	Maheshwari GK	NHL	40	NR
18	1998	MacLeod C	NHL (DLBCL)	51	CT, EBRT
19	2001	Yoon JH	NHL	Young,?	NR
20	2002	Tjalma WA	NHL (DLBCL)	73	NR
21	2008	Piura B	NHL	?	NR
22	2009	Koh LP	NHL (ALCL* <sup>1st</sup> )	?	CT, EBRT
23	2009	Tokatli F	NHL (Foll. B cell)	83	EBRT
24	2009	Zizi-Sermpetzoglou A	NHL	48	NR
25 <sup>th</sup> Present	2013	Verma YP	NHL (DLBCL)	35	EBRT, CT

EBRT-external beam radiotherapy, CT- chemotherapy, ?/NR-not reported/revealed

## DISCUSSION

Non-hodgkin lymphoma is heterogenous disease, varying from an indolent course to fulminating fatal one. Initial diagnosis by

Taussig in 1937 reported the first case of primary non-hodgkin lymphoma involving vulva (clitoris). On extensive search of published literature, since then, only twenty four cases have been found reported.<sup>4-12, Tab.1</sup> Non-Hodgkin lymphomas of the breast are also uncommon cancers which occur either as primary extra nodal diseases or as secondary localizations of a systemic disease. Primary breast lymphomas have a reported incidence ranging from 0.04% to 0.5% of all breast malignancies, account for less than 1% of all patients with non-Hodgkin's lymphomas and approximately for 1.7% of all extra nodal non-Hodgkin's lymphomas. The number of cases of primary NHL of the breast reported to date is around 250. Most of these cases have involved the right breast, and almost all the patients were females. NHLs of the breast typically present as unilateral mass; the frequency of bilateral disease at first presentation ranges from 5 –25%.<sup>2,3</sup>

pathologists is often missed as undifferentiated carcinoma. Immunohistochemical tests now can identify even the subtype of lymphoma. Majority of non-hodgkin lymphoma are of B cell lineage

and respond to treatment promptly. Diffuse lymphomas are more common and have a more unfavourable prognosis. In general, larger the cell type, whether follicular or diffuse, the poorer the prognosis.<sup>13</sup>

Treatment depends on histological subtype and clinical stage of disease, which may be surgery, radiotherapy, chemotherapy, or sometimes combined modality. Surgery has got limited role and is usually performed for diagnostic purpose. Most commonly used and effective first line chemotherapy regimen is CHOP (cyclophosphamide, adriamycin, vincristine and prednisolone). Chemotherapy provides remission rate of 70-80% and anticipated cure rate is approximately 35%. Relapse of disease even after complete remission is not unusual. Now, chemotherapy in combination with monoclonal antibody like Rituximab has shown even better results, though cost of therapy remains a constraint. But reported survival in vulvar lymphoma has been poor.

#### References:

1. Ferry J, Young R: Malignant lymphoma of the genitourinary tract. *Curr Diagn Pathol* 1997; 4:145-69.
2. Khan AS, Bakshi GD, Patel KK, Borse HG, Sankaye PB, Bhandarkar LD. Primary non-Hodgkin's lymphoma of the breast. *Bombay Hosp J*. 2002; 44:481-2.
3. Jeanneret-Sozzi W, Taghian A, Epelbaum R, Poortmans P, Zwahlen D, Amsler B, Villette S, Belkacémi Y, Nguyen T, Scalliet P, Maingon P, Gutiérrez C, Gastelblum P, Krengli M, Raad RA, Ozsahin M, Mirimanoff RO. BMC Cancer. Primary breast lymphoma: patient profile, outcome and prognostic factors. A multicentre Rare Cancer Network study. 2008 Apr 1; 8:86.
4. Kaplan EJ, Chadburn A, Caputo TA. Case report: HIV related primary non-Hodgkin's lymphoma of the vulva. *Gynecol Oncol*. 1996; 61:131-8.
5. Maheshwari GK, Baboo HA, Gopal U, Dave KS, Mehta S, Balar DB. Primary non-Hodgkin's lymphoma of the vulva: a case report. *Turkish Journal of Cancer*. 1998; 28(1):37-9
6. Macleod C, Palmer A, Findlay M: Primary non-Hodgkin's lymphoma of the vulva: a case report. *Int J Gynecol Cancer*. 1998; 8:504-8.
7. Yoon JH, Park YH, Chang KH, Ryu HS, Lee JP, Hahn JH, Oh KS. Primary non-Hodgkin's lymphoma of the vulva. *Korean J Gynecol Oncol Colposc*. 2001 Jun; 12(2):162-7.
8. Tjalma W, Van de Velde A, Schroyens W: Primary non-Hodgkin's lymphoma in Bartholin's gland. *Gynecol Oncol* 2002; 87:308-9.
9. Piura B, Rabinovich A, Shaco-Levy R. Vulval mass as the first manifestation of non-Hodgkin's lymphoma. *J Obstet Gynaecol*. 2008 Feb; 28(2):243-4.
10. Koh LP, Wong LC, Ng SB, Poon MLM, Low JJH. Primary cutaneous anaplastic large cell lymphoma of the vulva: a typical cutaneous lesion with an 'atypical' presenting site. *International Journal of Hematology*. October 2009; 90(3):388-91.
11. Tokatli F, Oz-Puyan F, Alas R, Usta U, Yilmaz H, Uzal C. Successful treatment of primary non-Hodgkin's lymphoma of the vulva with radiation therapy. *J BUON*. 2009 Jan-Mar; 14(1):119-22.
12. Zizi-Sermpetzoglou A, Petrakopoulou N, Tepelenis N, Savvaidou V, Vasilikaki T. Intravascular T-cell lymphoma of the vulva, CD30 positive: a case report. *Eur J Gynaecol Oncol*. 2009; 30(5): 586-8.
13. Kosari F, Daneshbod Y, Parwaresch R et al: Lymphomas of the female genital tract: a study of 186 cases and review of the literature. *Am J Surg Pathol*. 2005; 29: 1512-20.

#### How to cite this article:

Verma Y, Chauhan AK, Sabharwal R, Singh J: Unusual presentation of Non-Hodgkin Lymphoma: Vulva growth and Breast mass in the same patient. *OncoExpert* 2015; 1(1):31-34